Budapest Nephrology School
Secondary Hypertension

Debbie Cohen, MD
University of Pennsylvania
August 2010

UNIVERSITY of PENNSYLVANIA

Objectives

- Define Secondary Hypertension
- Incidence of secondary HTN
- Primary Hyperaldosteronism
- Pheochromocytoma
- Renal Artery Stenosis
- Determine who to work up for secondary HTN
- Best Screening tests for secondary hypertension

Secondary Hypertension

- 90% of patients have **essential** or primary hypertension
- These patients usually have **positive family history** of hypertension

- **Secondary hypertension** is when an underlying physiological or anatomical cause of hypertension is found

More common causes of Secondary Hypertension

- Renal Disease
- Renal Artery Stenosis
- Primary Hyperaldosteronism
- Pheochromocytoma

Primary Hyperaldosteronism

- Found to be increasingly common in patients with severe or resistant HTN
- May account for 5% of all hypertensives
- Reported in different series to be present in up to 38% of patients with resistant HTN

Primary Hyperaldosteronism

- Autonomous secretion of aldosterone from the adrenal cortex
- Elevated aldosterone levels result in suppression of renin levels
- Increased aldosterone results in sodium retention, HTN, loss of potassium in the urine, hypokalemia, metabolic alkalosis

Primary Hyperaldosteronism

- Conn’s Syndrome - Unilateral adrenal adenoma
- Bilateral Adrenal Hyperplasia
- Important to distinguish between these 2 causes as the treatment of the conditions differs

Diagnose Hyperaldosteronism

- Make a biochemical diagnosis before imaging
- Ratio of aldosterone: renin > 30:1
- Plasma aldosterone level > 15
- 24 hr urine aldosterone elevated

- Low or normal K levels
- Metabolic alkalosis

- If biochemical evidence, need imaging study to assess adenoma vs bilateral hyperplasia (CT abdomen)

Conn's Syndrome

- Unilateral adrenal adenoma
  - Specific appearance on CT scan due to increased fat content (<10 Hounsfield units)

- Treat surgically in most patients
  - Laparoscopic adrenalectomy
  - Adrenal Vein Sampling prior to surgery to confirm lateralization

- Can treat medically in mild cases, elderly or poor surgical candidates

Adrenal Adenoma

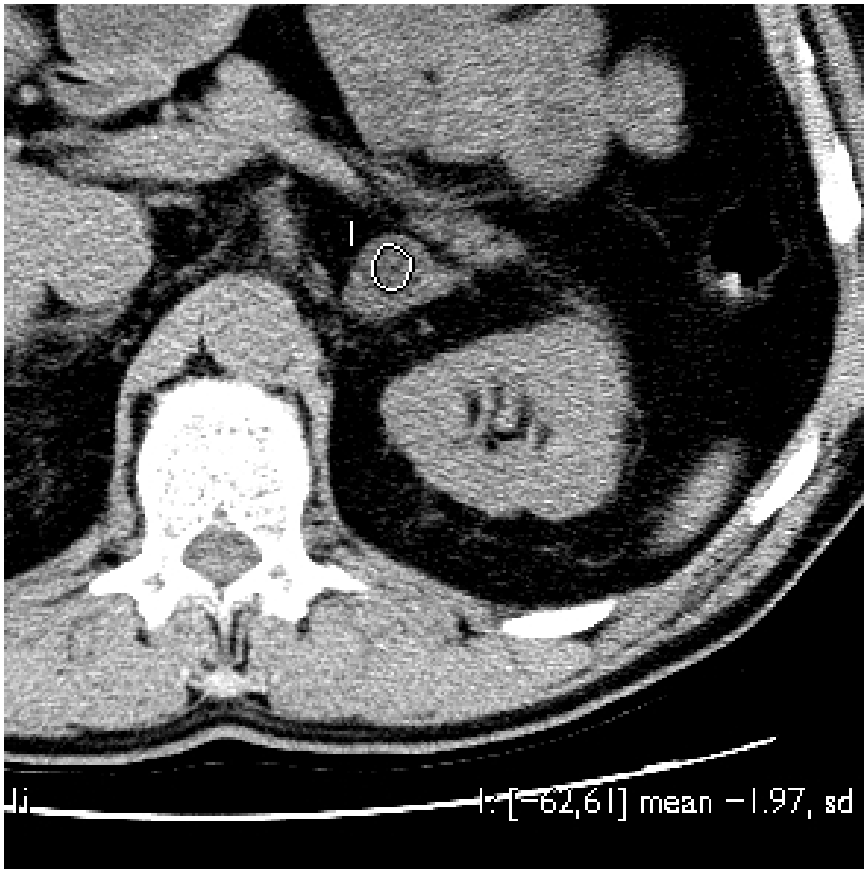

Bilateral Adrenal Hyperplasia

- CT abdomen: Bilateral Thickening or nodularity of Adrenal limbs
- Always treat **medically**
- **No role for surgery**
- Use aldosterone inhibiting drug: Aldactone, Eplerenone, Amiloride

Primary Aldosteronism

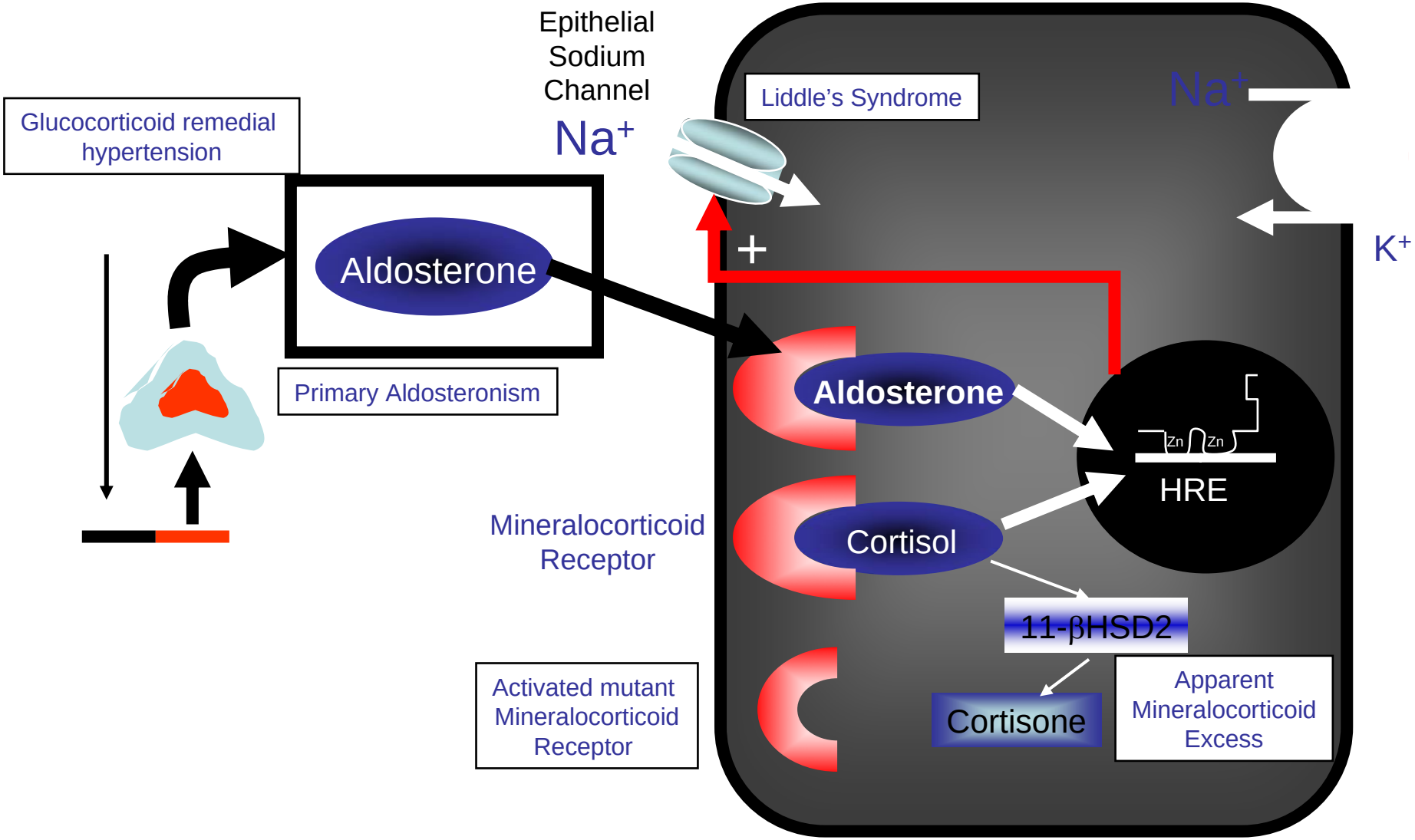

Primary Hyperaldosteronism

- Spironolactone - need to use high doses usually in the range of 50-100mg twice daily
- Is NOT tolerated by male patients
- Eplerenone - less potent but definitely less gynecomastia and less hyperkalemia
- Amiloride - well tolerated, occasionally GI side effects can use up to 10 mg twice daily, problem amiloride only comes in 5 mg tablets

IMAGING

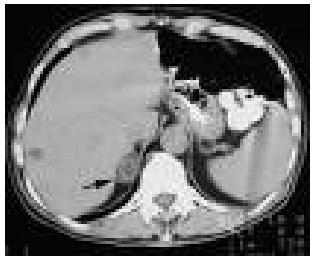

SAMPLING

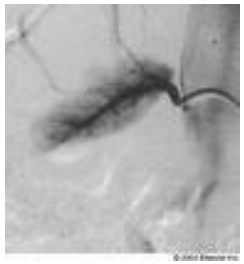

Lateralization index (LI) =
ipsilateral A/C ratio [ng/dL/mcg/dL]
over contralateral A/C ratio: 76/2.5=31

MAPPING

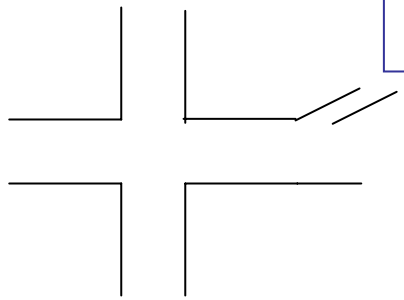

Selectivity index (SI) = ratio of cortisol level in each adrenal vein compared with IVC.
Right 1090/23 = 47
Left 680/23=30

AVS Results

	Aldo	Cortisol	Ratio
R adrenal	2590	1090	**2.5**
L adrenal	**52 100**	**680**	**76**
IVC	110	23	4.7

Primary Hyperaldosteronism

- More common than previously thought
- Worthwhile screening patients particularly with severe or resistant hypertension
- Potential cure of HTN

Pheochromocytoma

- Rare cause of hypertension
- Approximately 800 new cases diagnosed annually in the United States
- Penn: 30-40 new cases per year and 70-100 patients in follow up per year

Autonomic nervous system

- Innervates vascular and visceral smooth muscle, exocrine and endocrine glands, and parenchymal glands throughout the organs

- Two divisions
  - Sympathetic chain, includes the adrenal medulla
  - Parasympathetic ganglia

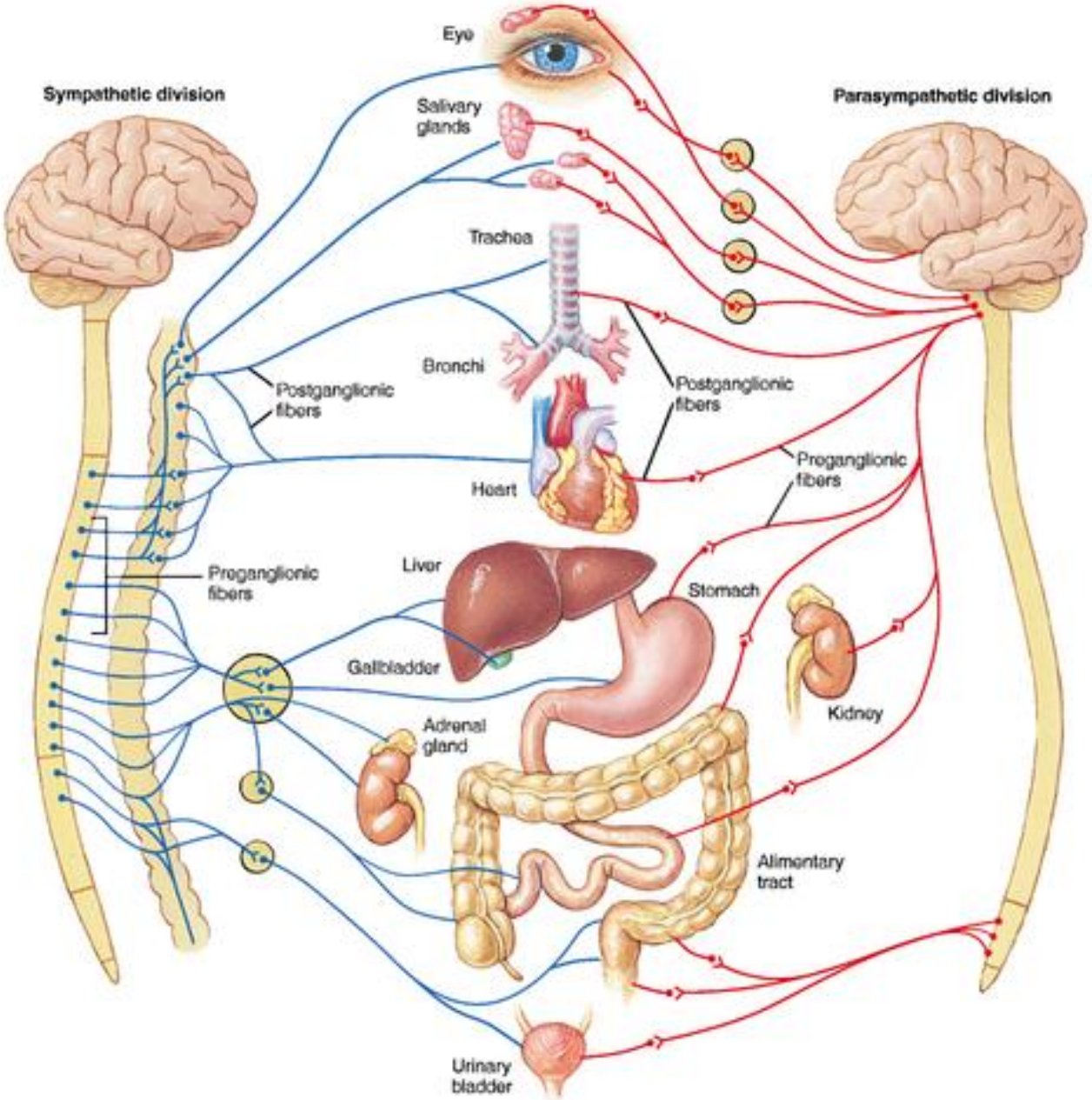
Eye
Sympathetic division
Parasympathetic division
Salivary glands
Trachea
Bronchi
Postganglionic fibers
Postganglionic fibers
Preganglionic fibers
Heart
Preganglionic fibers
Liver
Stomach
Gallbladder
Kidney
Adrenal gland
Alimentary tract
Urinary bladder

Tumors of the Autonomic Nervous System

- **Adrenal medulla**
  - **Pheochromocytoma**

- **Sympathetic chain**
  - Sympathetic paraganglioma – usually located retroperitoneal, but can be found in abdomen or thorax, usually secrete catecholamines
    - Usually termed **extra adrenal pheochromocytoma**

- **Parasympathetic ganglia**
  - Parasympathetic paraganglioma usually in the head and neck region, generally biochemically silent
    - **Glomus tumors, chemodectomas, carotid body tumors**

Sites of Paraganglionomas

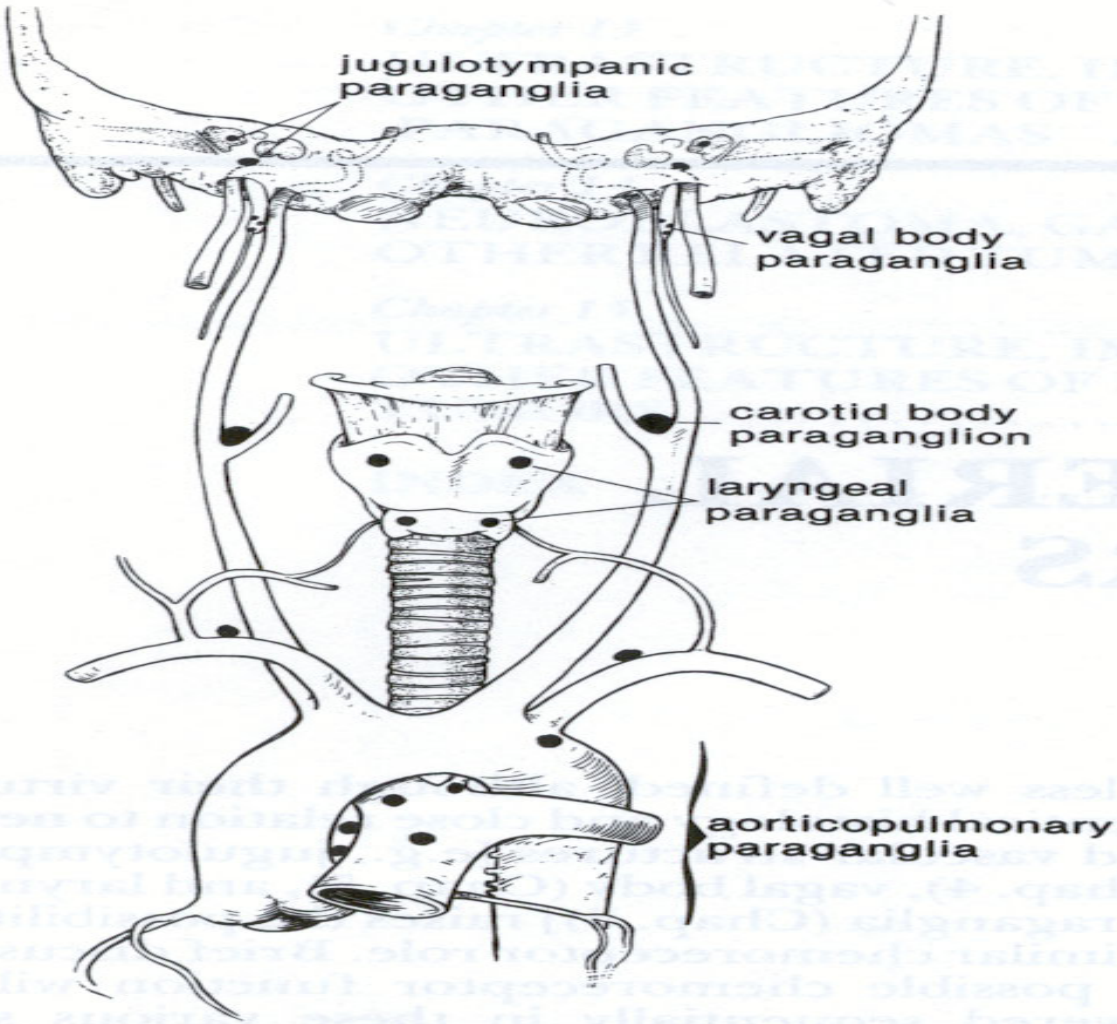

Pheochromocytoma

- Chromaffin cells are derived from the neural crest which function as post-synaptic nerve cells
- Unregulated growth of chromaffin cells results in the development of pheochromocytomas which can occur in the adrenal gland or in an extra-adrenal location
- Norepinephrine (NE) is converted to epinephrine (E) in the adrenal medulla
- Pheo - Increased catecholamine secretion
- NE is predominantly excreted and causes intense stimulation of alpha receptors

Pheochromocytoma

- Alpha receptors are stimulated resulting in hypertension, tachycardia, palpitations and headaches
- Not all patients have these classic symptoms
- BP can be labile
- Rare cause of hypertension

Pheochromocytoma

- Previously “10%” tumor

- 90% of lesions are found in the adrenal gland
- 10% extra-adrenal (paraganglionomas)
- 10% bilateral
- (10%) 20-30% malignant
- 30-40 % genetic in origin

Metabolic Pathway

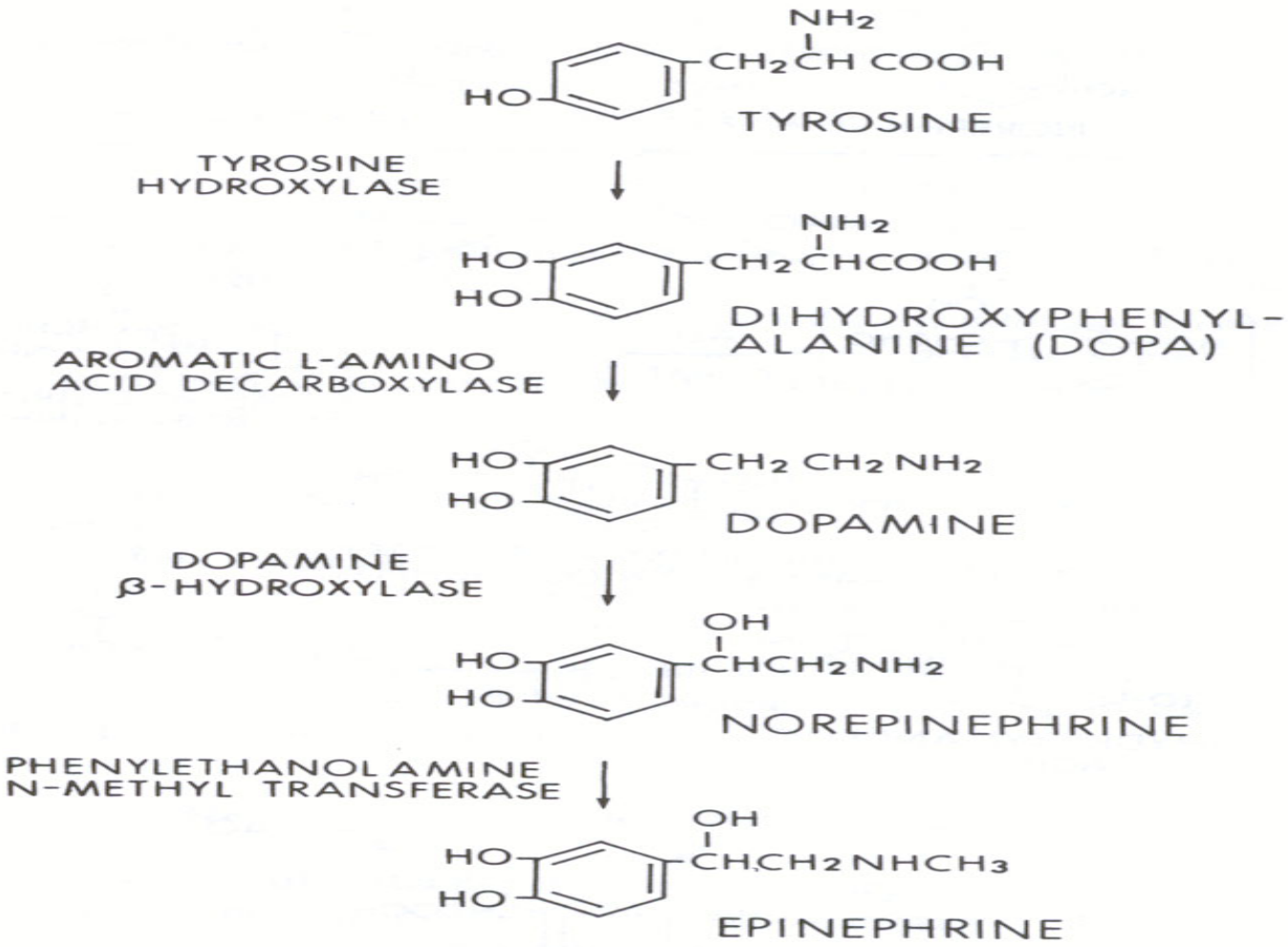

FIG. 1. Catecholamine biosynthesis.

Metabolic Pathway

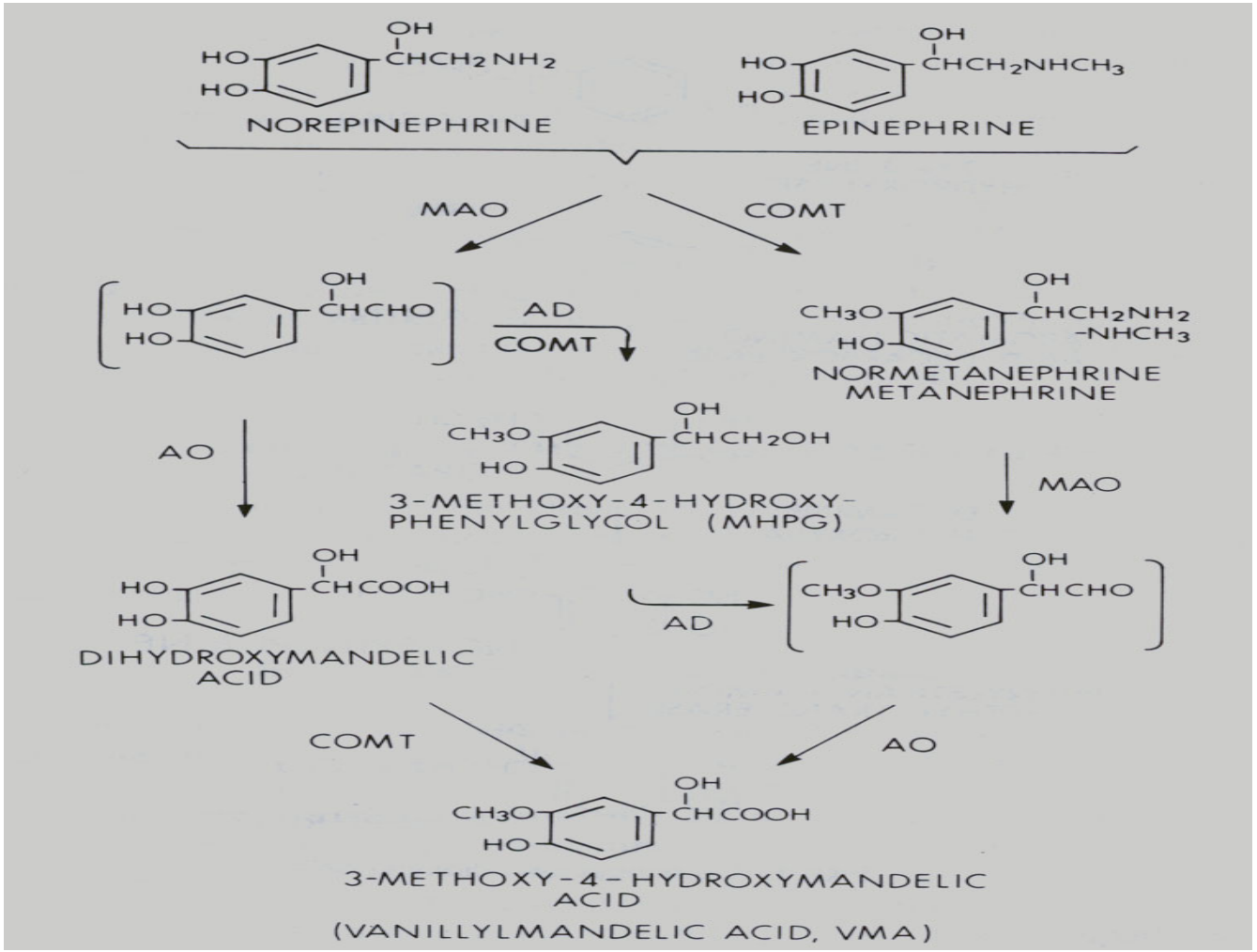

Plasma Metanephrines

- Newest measure, most sensitive and specific
- Initially recommended that levels are drawn after 20 minute rest and in fasting state
- No acetaminophen for 5 days
- Newer data shows that levels can be done without rest period but need to be interpreted with higher upper limit of normal
- If borderline values can repeat supine after rest or order 24 hour urine

24 hour urine for catecholamines

- Previously most reliable test
- Order metanephrines, catecholamines, VMA
- Total urine metanephrines - most useful, not affected by drugs or food
- False positive with certain drugs: labetalol, clonidine and buspar
- Increase in VMA alone due to ingestion of vanilla products

How to screen for pheo in dialysis patients

- Cannot measure 24 hr urines
- Plasma catecholamines have been shown to consistently elevated in HD patients but never more than 3-fold (Mayo)
- Plasma catecholamine levels are inversely elevated with decreasing renal function
- Study from NIH showed plasma free metanephrines are relatively independent of renal function and are, therefore, more suitable for diagnosis of pheochromocytoma among patients with renal failure or in dialysis patients

Diagnosis of Pheochromocytoma

- Plasma metanephrines **(BEST SCREENING TEST)**
- 24 hour urine for catecholamines, metanephrines, VMA
- Values are usually 3-4 x greater than normal
- If borderline values and strong clinical suspicion, can pursue further testing

Other Screening Tests

- **Plasma Catecholamines** - less reliable, often abnormal, do not order as a screening test

- **Clonidine suppression test** - difficult, rarely done

- **Chromogranin A**- co-stored and co-secreted with catecholamines, levels increased in 80% of pts with pheo
- Decreased utility as it has a low specificity
- Useful to follow patients with metastatic disease

Biochemical Testing

	Hereditary	Spontaneous
	sensitivity/specificity	sensitivity/specificity
Plasma Met	97/96	99/82
Plasma Cat	69/89	92/72
Urine Met	96/82	97/45
Urine Cat	79/96	91/75
Total Urine Met	60/97	88/89
VMA	46/99	77/86

Pheochromocytoma

- If biochemical tests are positive, patient need radiographic imaging to localize the tumor
- CT/MRI abdomen (adrenal glands)

MRI upper abdomen

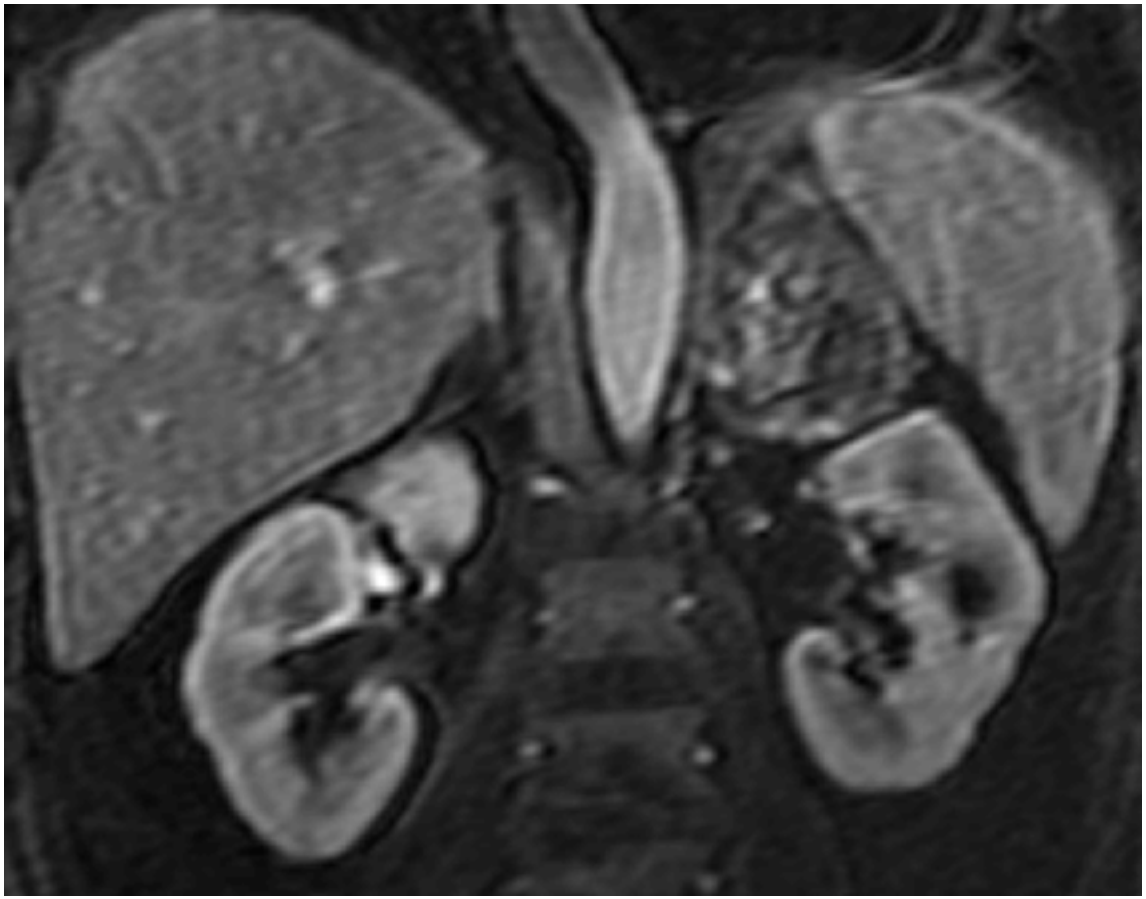

Once diagnosis is confirmed, how to proceed

- Treatment of choice is laparoscopic adrenalectomy for adrenal tumors
- Adrenal sparing surgery if possible if bilateral tumors
- Patients need to be well prepared prior to surgery as major morbidity is associated with removal of these tumors

Catecholamine Biosynthesis

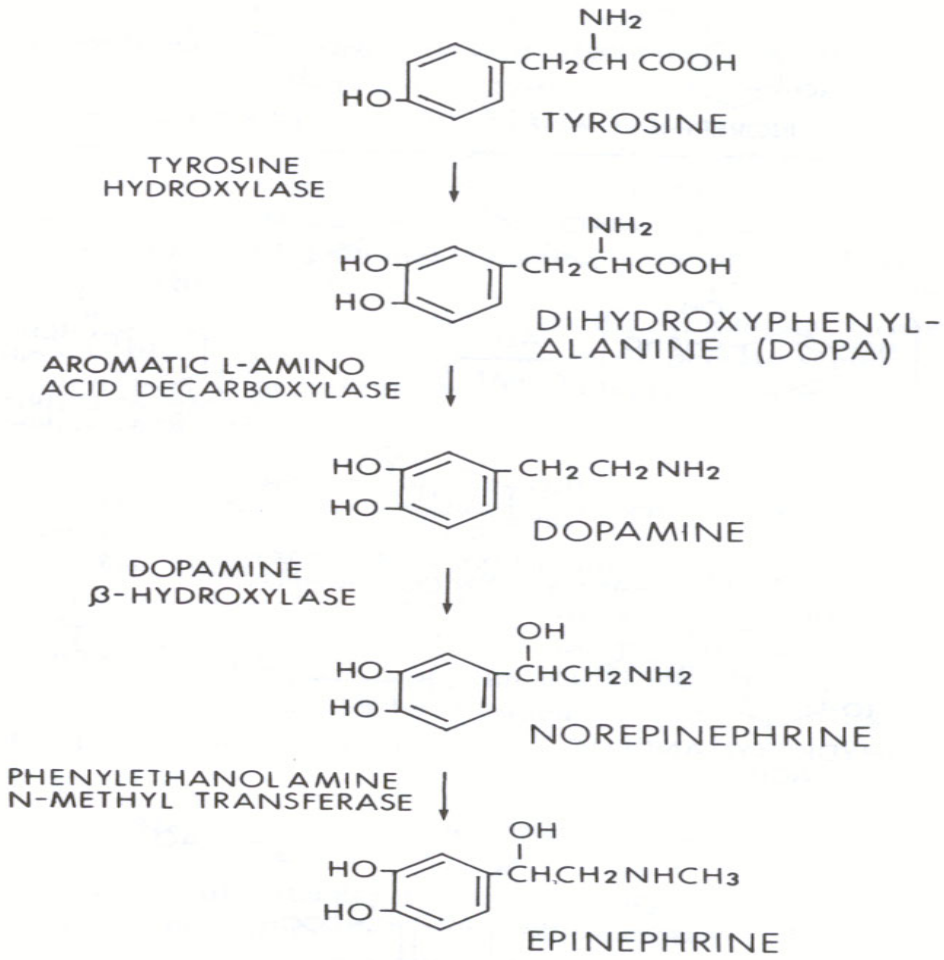

FIG. 1. Catecholamine biosynthesis.

Pre-operative preparation

- Peripheral alpha blocker : phenoxybenzamine 10-60 mg
- Side Effects: severe postural hypotension, tachycardia, nasal congestion, GI side effects
- Begin 2-3 weeks prior to surgery or as soon as diagnosis is confirmed

Pre-operative preparation

- Never use beta-blocker until fully alpha blocked as can get unopposed stimulation of alpha receptors

- Once alpha-blocked, if tachycardic can add beta blocker

Pre-operative preparation

- Alpha-methyl tyrosine(demser) prevents conversion of catecholamines to active form
- Blocks Tyrosine Hydroxylase preventing conversion of tyrosine to L-dopa
- Begin 2 weeks prior to surgery, titrate dose
- Side effects: extra pyramidal neurological problems, severe lethargy, GI side effects

During Surgery

- Use IV phentolamine (alpha blocker) to maintain BP and prevent BP surges
- Typical response is to see BP surges when tumor is manipulated and severe hypotension once tumor is removed
- Post - op usually require alpha agonist to support BP (norepinephrine) for first 48 hours

Post-op follow up

- Repeat 24 hr urine and/or plasma metanephrines at 6 weeks and every 6 -12 months after
- There is a possibility of recurrence
- Recurrence more likely with malignant tumors and extra-adrenal tumors

Benign vs Malignant

- 80% - benign, 20-30% - malignant
- Very difficult to distinguish benign vs. malignant
- Histologically can appear identical
- Extra-adrenal tumors, multiple sites more likely to be malignant
- Macroscopic appearance of tumor may be helpful - tumor encapsulated, local invasion or distant metastases
- Most tumors are indolent and slow growing
- Certain tumors associated with SDHB mutation can be highly malignant and very aggressive

Histology

- **Pass Score (**pheochromocytoma of the adrenal gland scoring scale): scoring system (maximum score is 20) is based on the presence of 12 different histologic parameters, including tumor necrosis, mitotic rate, tumor cell spindling, and the presence of large cell nests

- >6 high malignant potential
- 4-6 need close follow up
- <4 low malignant potential

Imaging studies for metastatic disease

- Octreotide scan - not often used
- MIBG 131
- MIBG 123
- FDG PET scan (SDHB)
- FDA PET scan

MIBG Scan

- Nuclear medicine scan which shows increased area of radio-active tracer in area of excess catecholamine secretion
- MIBG: resembles NE and is taken up by adrenergic tissue
- **I -131:** more commonly done, need to pre-treat with lugols iodine to prevent thyroid crisis, less sensitive than I-123, used in treatment of pheo (MIBG therapy)
- **I - 123:** very difficult to obtain, now available at Penn, better imaging and more sensitive for pheo, need minimal iodine prep

Treatment Options For Malignant Pheo

- Not well defined
- Watch and wait
- Chemo - several regimens have been tried with minimal response in most cases
- Radiation reserved usually for bone metastases
- **Radio-active MIBG - best option**
- Surgery - debulking
- ?VEGF inhibitors

MIBG Treatment

- High dose MIBG used in the past but increased toxicity
- Currently at PENN using low dose MIBG of 2mCi/kg every 3-4 months
- Maximum dose of 1000 mCi/kg
- Monitor CBC weekly for 8 weeks
- Well tolerated and done as an outpatient procedure
- New trial evaluating different form of delivery of MIBG (Azedra) with higher dose MIBG

Genetic syndromes with Pheo/PGL

Syndrome	Gene	Chr	Major component	Other manifestations
PGL 1*	***SDHD***	11q23	PHEO or PGL	--------
PGL 2*	Unknown	11q13	PGL	--------
PGL 3	***SDHC***	1q21-23	PGL	--------
PGL 4	***SDHB***	1p36	PGL	Renal clear cell cancer
Carney triad	Unknown		PHEO	Gastric leiomyosarcoma Pulmonary chondroma Adrenal adenoma
Familial PGL and gastric stromal sarcoma	Unknown		PGL	Gastric stromal sarcoma
VHL	*VHL*	3p25-26	PHEO	Hemangioblastomas (brain, spine, retina) Renal clear cell cancer Pheochromocytoma
MEN 2	*RET*	10q11.2	PHEO	Medullary thyroid carcinoma Parathyroid hyperplasia
NF 1	*GNDF*	17q11	PHEO	Neurofibromas, café-au-lait spots Lisch nodules Plexiform neurofibromas Malignant peripheral nerve sheath tumors

Carotid body tumors

- In 1987 reported that people living in the Andes had an increased incidence of carotid body tumors (1987)
- High altitude causes chronic hypoxia
- Report from 1970s showing that patients in the Andes with carotid body tumors had increased succinate levels
- In 2000 linkage studies from families in the Netherlands in with apparent pheo/PGL syndromes showed mutations in the SDH complex

Familial pheo/PGL

- Succinate dehydrogenase (SDH) catalyzes the conversion of succinate to fumarate in the Krebs cycle

- Succinate dehydrogenase (SDH) or mitochondrial complex II is comprised by four subunits (A–D) in the inner mitochondrial membrane

- SDH subunits are encoded by autosomal genes

SDH complex

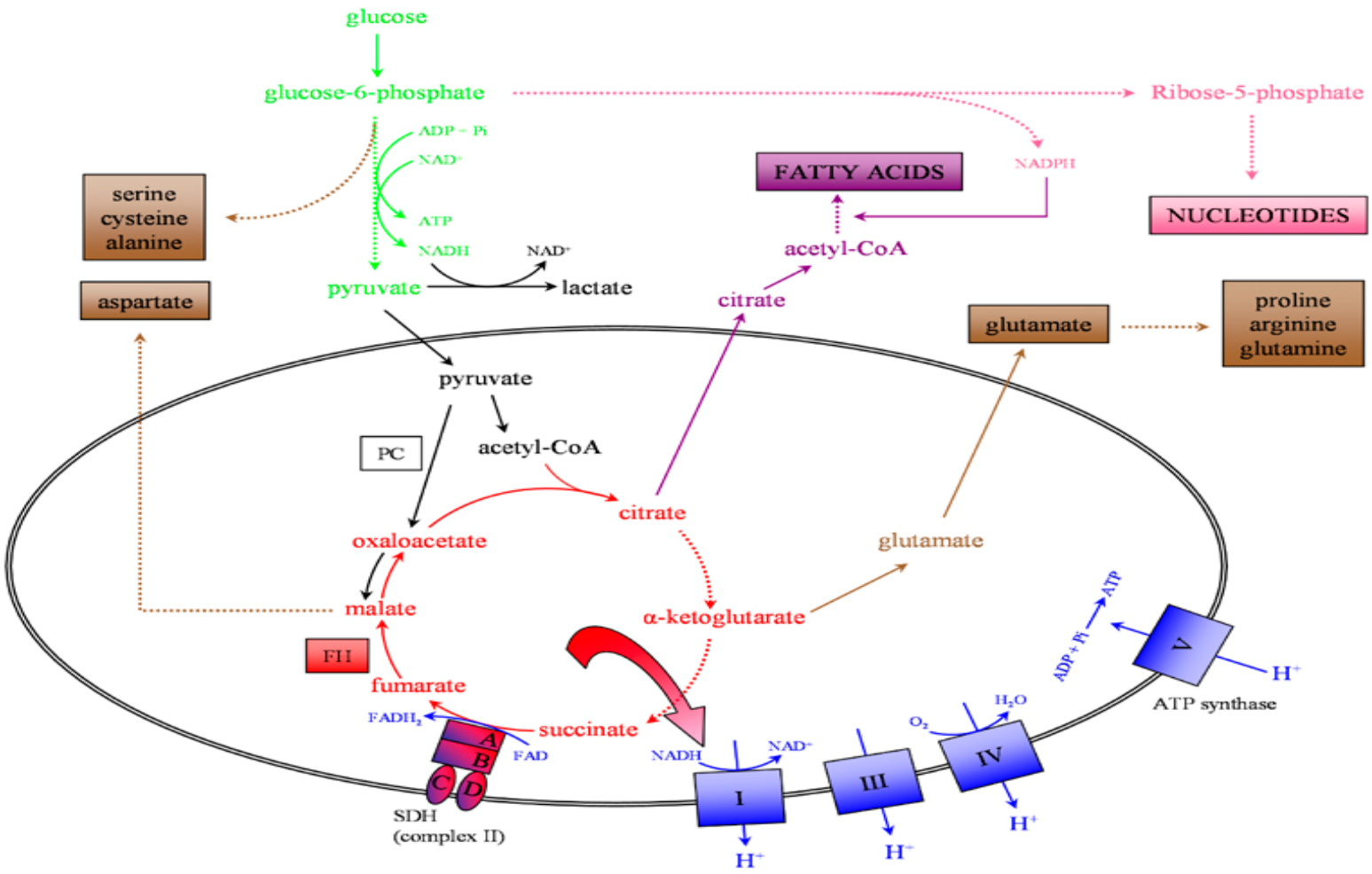
glucose
glucose-6-phosphate
Ribose-5-phosphate
ADP + Pi
NAD+
ATP
NADH
NAD+
pyruvate
lactate
serine
cysteine
alanine
aspartate
FATTY ACIDS
NADPH
NUCLEOTIDES
acetyl-CoA
citrate
glutamate
proline
arginine
glutamine
pyruvate
PC
acetyl-CoA
citrate
oxaloacetate
glutamate
malate
α-ketoglutarate
FH
fumarate
FADH2
succinate
FAD
A
B
C
D
SDH
(complex II)
NADH
NAD+
I
III
IV
V
H+
H+
H+
O2
H2O
ADP + Pi
ATP
H+
ATP synthase

- Germline heterozygous mutations in SDHD were found to cause familial and apparently sporadic pheochromocytoma/PGL (2000)
- Subsequently, germline heterozygous mutations in SDHB and SDHC were also found in heritable pheo and PGL
- Recent mutations identified in SDHA
- SDHB mutations have been associated with malignancy, decreased survival and renal cell carcinoma

What is the Difference SDHB/C/D PGL

Familial PGL Syndrome	**PGL1**	**PGL3**	**PGL4**
SDH subunit	**SDHD**	**SDHC**	**SDHB**
Mutation in gene locus	11q23	1q21	1p35-36.1
	Baysal 2000	Niemann 2000	Astuti 2001

What is the Difference SDHB/C/D PGL

	SDHD	SDHC	SDHB
Chest/abdomen/pelvis	++	+	**+++**
Adrenal	++	+	**+**
Extra-adrenal	+	+	**+++**
multifocal	+	_	**++**
malignant	rare	_	**+++**
Head/Neck	+++	+++	**++**
multifocal	+++	_	**+**
malignant	Rare	Rare	**Rare**

Using von-Hippel Lindau as a model to connect HIF and VEGF

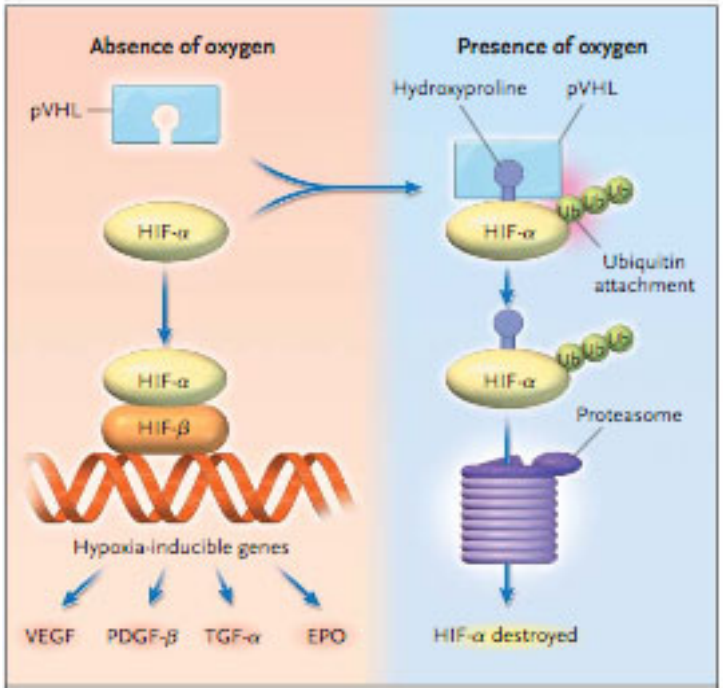

Control of Hypoxia-Inducible Factor (HIF) by the Gene Product of the von Hippel–Lindau Gene (pVHL).

HIF is a heterodimer consisting of an α subunit and a β subunit. In the presence of oxygen, HIF-α is hydroxylated on one of two proline residues. The pVHL binds to hydroxylated HIF-α and directs the attachment of a polyubiquitin chain, which targets HIF-α for destruction by a multiprotein complex called the proteasome. Under hypoxic conditions, or in the absence of pVHL, HIF-α accumulates and activates the transcription of hypoxia-inducible genes. VEGF denotes vascular endothelial growth factor, PDGF-β platelet-derived growth factor β, TGF-α transforming growth factor α, and EPO erythropoietin.

Genetic Testing

Consider genetic testing in sporadic pheochromocytoma if age at diagnosis < 50 for mutations in

VHL, *RET*, *SDHD*, *SDHB*

using the patient's findings and table below as a guide

Syndrome	Gene	Average age of diagnosis	Adrenal disease	Multifocal adrenal disease	Extra-adrenal disease	Predominant biochemical profile	Mutation frequency
MEN 2	*RET*	35-40	++	++	-	Metanephrine	low
VHL	*VHL*	20-30	++	++	+	Normetanephrine	high
SDHB	*SDHB*	20-30	+	-	++	Unknown	low
SDHD	*SDHD*	20-30	+	+	++	Unknown	medium

Genetic Testing

- SDHB and SDHD mutations are increasingly being detected
- Autosomal dominant mutations
- Affected family members require annual screening
- Screening guidelines controversial
- What age to start screening (? age 5)

Pheo/PGL

- The diagnosis and management of both adrenal and extra-adrenal pheos remain a diagnostic challenge
- Plasma metanephrines best screening test
- Levels greater than 4X normal definite pheo
- Refer all patients for genetic testing
- SDHB/SDHD mutations increasingly common
- Future challenges remain in treatment for metastatic disease and predicting who will have a poor outcome

Renal Artery Stenosis

- FMD: young females
- FMD: CT angiogram best screening
- FMD: can be missed with MRA

- FMD: can be bilateral, has excellent results with angioplasty, usually does not recur and does not need stenting

FIBROMUSCULAR DYSPLASIA: RENAL ARTERIOGRAM

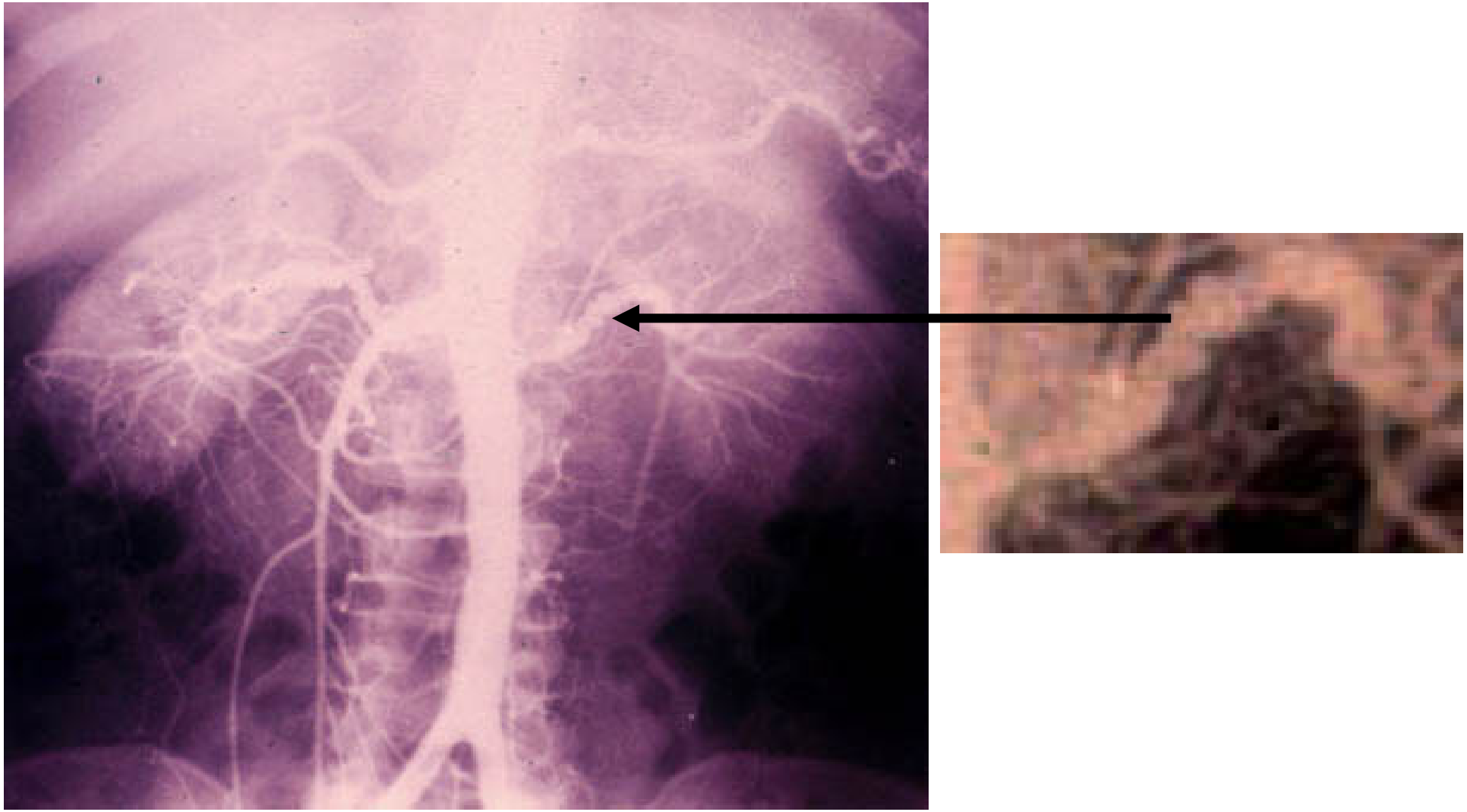

Renovascular Hypertension

- Prevalence: 1-2% hypertensives
- Mechanism: Excessive renin secretion with increased Angiotensin II
- Presentation: Older patients, history of atherosclerotic disease, e.g. CAD, *SMOKER*
- Diagnosis:
  - Screening Test –MRA or CT angiogram [NSF!]
  - Confirmation: Angiogram-Radiocontrast or CO_2
- Management:
  - Antihypertensive including ACE or ARB
  - Angioplasty and Stent

RAS

- Dilemma as which test to use when screening for atherosclerotic RAS - this type of patient usually has DM and CKD so want to avoid iodinated IV contrast and Gadolinium

- Doppler studies very operator dependent and may be unreliable

- Angiography is the gold standard

Managing RVD

- Unilateral RVD – angioplasty and medical therapy are similar in control
- Bilateral RVD – usually will require more medication if managed medically; ischemic nephropathy may prompt angioplasty/surgery
- There is no “standard” antihypertensive regimen
- There is no standard of care

Sleep Apnea

- Worthwhile getting sleep study in resistant HTN as if diagnosed with sleep apnea often see improvement in BP control with use of CPAP

Who to work up for secondary HTN

- All young patients (<30yrs)
- New onset hypertension in older patients >70 years
- Sudden worsening of previously well controlled hypertension
- Strong suspicion for secondary HTN
- Negative family history for HTN
- Unusually severe HTN

Who to work up for Secondary HTN

- Unprovoked hypokalemia
- Triad of symptoms: headache, sweating and palpitations
- Epigastric bruit (RAS)
- Different BP measurements in the arms and legs or radiofemoral pulse delay
- Drug resistant hypertension

Initial Evaluation for Secondary HTN

- Plasma Renin
- Plasma aldosterone
- Plasma metanephrines
- CT angiogram / MRA
- Sleep study

Conclusion

- Secondary Hypertension accounts for 10% of hypertension
- Need to decide which patients are worthwhile to evaluate for secondary hypertension
- If diagnosis is confirmed, may be potentially curative form of HTN especially in a young patient


Glenfiddich
PRINCESS